

PediatricsinReview®

Acute Testicular Disorders
John M. Gatti and J. Patrick Murphy
Pediatrics in Review 2008;29;235
DOI: 10.1542/pir.29-7-235

The online version of this article, along with updated information and services, is located on the World Wide Web at:
<http://pedsinreview.aappublications.org/content/29/7/235>

Pediatrics in Review is the official journal of the American Academy of Pediatrics. A monthly publication, it has been published continuously since 1979. Pediatrics in Review is owned, published, and trademarked by the American Academy of Pediatrics, 141 Northwest Point Boulevard, Elk Grove Village, Illinois, 60007. Copyright © 2008 by the American Academy of Pediatrics. All rights reserved. Print ISSN: 0191-9601.

American Academy of Pediatrics

DEDICATED TO THE HEALTH OF ALL CHILDREN™



Acute Testicular Disorders

John M. Gatti, MD,*
J. Patrick Murphy, MD[†]

Author Disclosure
Drs Gatti and Murphy
have disclosed no
financial relationships
relevant to this
article. This
commentary does not
contain a discussion
of an unapproved/
investigative use of a
commercial
product/device.

Objectives After completing this article, readers should be able to:

1. Describe the appropriate evaluation and management of the acute scrotum.
2. Discern testicular torsion from other, less urgent conditions that may mimic it.
3. Discuss the importance of prompt diagnosis and treatment of testicular torsion for gonadal salvage.

Introduction

Acute scrotal pain with or without swelling and erythema in the child or adolescent male should be treated as an emergent condition. The differential diagnosis includes: torsion of the spermatic cord, appendix testis or epididymis, epididymitis/orchitis, hernia, hydrocele, trauma, sexual abuse, tumor, idiopathic scrotal edema (dermatitis/insect bite), cellulitis, and vasculitis (Henoch–Schönlein purpura). Most of the conditions are nonemergent, but the prompt diagnosis and treatment of torsion of the spermatic cord is imperative to avoid permanent ischemic damage to the testicle. The most common causes of acute scrotal pain are testicular (spermatic cord) torsion and torsion of the rudimentary vestigial appendages of the testicle or epididymis. The child's age suggests the cause of the acutely painful scrotum because torsion of the appendix testes/epididymis is more common in prepubertal boys and spermatic cord torsion occurs more frequently in adolescents and newborns.

Testicular Torsion

Torsion of the testicle results from twisting of the spermatic cord, which compromises testicular blood supply. The number of twists determines the amount of vascular impairment, although generally a 4- to 8-hour window exists before significant ischemic damage occurs that can affect long-term testicular morphology and sperm formation. Testicular torsion is a true surgical emergency. Adolescent males tend to present beyond the “golden” 4- to 8-hour period, but urgent surgical treatment is indicated because viability of the testis is difficult to predict.

Two types of testicular torsion may occur. Extravaginal torsion results from twisting of the cord proximal to the tunica vaginalis. This mechanism occurs perinatally during descent of the testicle before the scrotal investment of the tunica vaginalis has taken place, allowing the tunica and testis to spin on their vascular pedicles. The tunica vaginalis likely becomes adherent to the surrounding tissues by 6 weeks of age.

Intravaginal torsion occurs beyond the perinatal period and can result from abnormal fixation of the testicle and epididymis within the tunica vaginalis. Normally, the tunica invests the epididymis and posterior surface of the testicle, which fixes it to the scrotum and prevents it from twisting (Fig. 1). If the tunica vaginalis attaches in a more proximal position on the spermatic cord, the testicle and epididymis hang free in the scrotum and can twist within the tunica vaginalis. Such abnormal fixation is described classically as the “bell-clapper” deformity and occurs in only a minority of males (Fig. 2). This type of deformity is common, as discerned by autopsy studies, and usually is bilateral. Because testicular torsion occurs relatively infrequently, other factors also play a role in its occurrence.

Rapid growth and increasing vascularity of the testicle also may be precursors to torsion.

*Associate Professor, University of Missouri at Kansas City School of Medicine; Director, Minimally Invasive Urology, Children's Mercy Hospital, Kansas City, Kan.

[†]Professor, University of Missouri at Kansas City School of Medicine; Chief, Section of Urology, Children's Mercy Hospital, Kansas City, Kan.

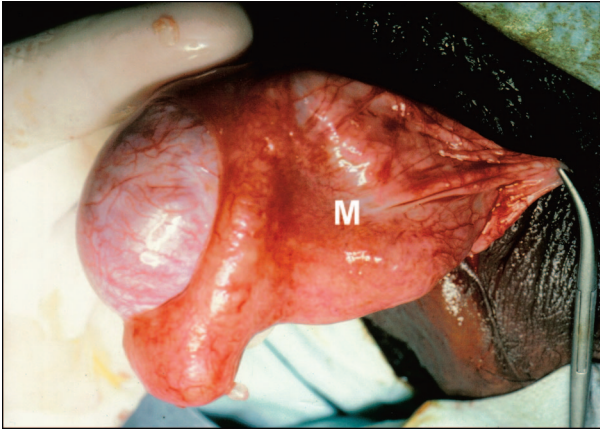


Figure 1. Intraoperative example of testicle that has a normal, wide mesentery (M) and good intrascrotal fixation, not susceptible to torsion.

This phenomenon occurs at puberty and is believed to account for the age distribution of torsion, which increases in adolescence. Rapid cremasteric muscle contraction elevates the testicle and can have a rotational effect on the spermatic cord that can induce torsion. The congestion associated with an inflammatory process or minor trauma also may predispose to torsion in a male who has a “bell-clapper” deformity. It is especially important to maintain a high level of suspicion in boys who experience increasing pain after being diagnosed as having epididymitis or mild blunt scrotal trauma, who may have developed testicular torsion as a secondary event.

Clinical Findings

The sudden onset of severe unilateral pain, often with nausea and vomiting, is the classic presentation of testic-

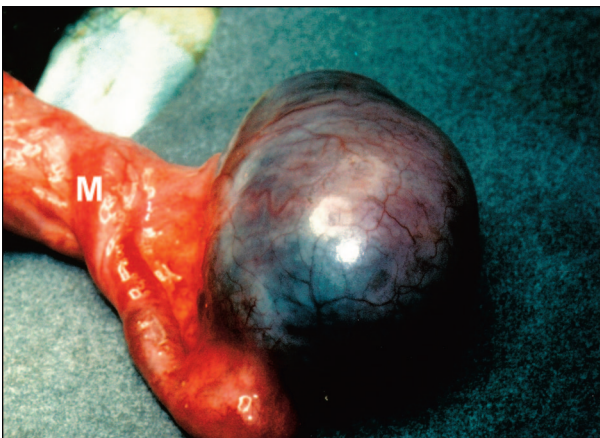


Figure 2. Intraoperative example of detorsed testicle that has a narrow mesentery (M) and poor intrascrotal fixation (“bell-clapper” deformity).

ular torsion. The pain usually is unrelenting, but seemingly minimal pain may occur in patients who are very stoic or when the torsion has been longstanding. A history of previous bouts of intermittent testicular pain may be given and likely represents previous intermittent torsion and detorsion.

The physical examination should include an investigation of the abdomen, inguinal area, and scrotum. The abdomen and inguinal area should be inspected for other causes of scrotal pain, such as an inguinal hernia. Depending on the duration of the torsion, the scrotum can show various degrees of erythema and induration. If landmarks are still present, the involved testicle may be riding higher, have a transverse orientation, or have the epididymis located anteriorly. The cremasteric reflex frequently is absent in patients who have torsion, but presence of the cremasteric reflex certainly does not exclude torsion. The testicle usually is palpably tender when there is spermatic cord torsion, whereas the focal area of tenderness is in the superior testis or caput epididymis when the patient has a torted appendix testis or epididymitis. In the later stages of testicular torsion, scrotal edema and erythema may obliterate these landmarks, making the examination more difficult.

Manual detorsion may be attempted when torsion is suspected and the patient’s pain tolerance allows it. Classically, detorsion should be attempted in a medial to lateral or “open book” rotation. If successful, the testicle changes its orientation and usually drops lower in the scrotum. The patient reports sudden pain relief. The direction of rotation described is only the case in about two thirds of patients, and if the initial attempt at outward rotation is unsuccessful, an attempt in the other direction may be made. Analgesics are helpful when attempting this procedure. Because manual detorsion may not detorse the cord totally, prompt surgical exploration still is required. Manual detorsion may play a role in decreasing the degree of ischemia when a substantial delay in reaching the operating room is anticipated, but it is not a substitute for exploration and fixation.

Other diagnostic studies may help determine the cause of the acutely painful scrotum. Urinalysis is indicated because pyuria and bacteriuria are more likely in infectious epididymitis/orchitis. High-resolution ultrasonography with color-flow Doppler and radionuclide imaging are two studies that provide information about testicular blood flow. Most clinicians use these studies to help confirm a clinical diagnosis other than testicular torsion.

Radionuclide imaging of the scrotum was, at one time, the study of choice. Ultrasonography with color

Doppler now has become a more popular study in most institutions because it allows determination of blood flow, is less time-consuming, is more readily available, and does not expose the patient to ionizing radiation. It also is highly reliable in experienced hands.

The ability to evaluate the testicle and spermatic cord anatomically is an additional advantage of ultrasonography. Coiling of the spermatic cord, indicating testicular torsion, may be detected even when testicular blood flow is normal. Such studies are adjunctive to the clinical evaluation for testicular torsion and are used when that diagnosis is equivocal. If torsion is strongly suspected by history and physical findings, imaging only wastes time when emergent surgical exploration is indicated.

Surgical Correction

Surgical exploration should be undertaken with as little delay as possible when torsion is suspected. Most surgeons use a midline median raphe incision, entering the symptomatic hemiscrotum initially to deliver the testicle and allow detorsion. With the torsion relieved, the testicle is placed in warm, moist sponges while the opposite hemiscrotum is explored. The contralateral testis is fixed in three positions with nonabsorbable suture. The suture should attach the testicle to the scrotal wall, excluding the tunica vaginalis by excising a portion or tucking it back into the scrotum.

This technique allows better fixation of the testicle to the scrotal connective tissue, much like the dartos pouch fixation used in newborn scrotal fixation.

The ipsilateral testis then is reassessed. If it is obviously nonviable, it is removed. If it is reperfused or fresh bleeding can be seen from the cut surface, it should be replaced into the scrotum and fixed in the same fashion as the contralateral testis. Testicular fixation is not an absolute guarantee against the possibility of future torsion; cases of torsion after fixation have been reported. Any patient presenting with suspected testicular torsion should be evaluated and treated with the same diligence, whether or not a previous fixation has been performed.

Antisperm antibodies can be formed in response to testicular damage in the torsed gonad, raising concern about later damage to the contralateral testis. Although such damage has been demonstrated in animals, whether this antibody response is physiologically significant in humans remains a question. Because of speculation that an immune response to testicular damage in the torsed

gonad may be responsible for later effects on the other testis, some suggest removal of all testes that have experienced any significant ischemic change. Our practice is to remove the testis only if it appears nonviable.

Intermittent Testicular Torsion

A number of boys who present with torsion have a history of prior acute episodes of testicular pain that resolve spontaneously. Unfortunately, intermittent testicular pain in adolescent males is not an unusual complaint. Such episodes may represent intermittent torsion with spontaneous resolution. In adolescent males who present with a history of significant acute testicular pain that has resolved (particularly with multiple events), intermittent testicular torsion should be strongly considered. Transverse testicular orientation or excess testicular mobility on physical examination adds to this suspicion.

Doppler ultrasonography performed while the patient has symptoms provides the diagnosis, but such a study may be difficult to obtain in a timely fashion. In this scenario, even with normal examination findings, elective

Surgical exploration should be undertaken with as little delay as possible when torsion is suspected.

scrotal exploration looking for a “bell-clapper” deformity may be warranted. Scrotal ultrasonography prior to elective exploration ensures that no inapparent testicular lesions are present.

Perinatal Testicular Torsion

Perinatal torsion is a term used to include both prenatal and postnatal events. The difference between the two types of torsion is important but sometimes may be difficult to determine clinically. Prenatal torsion classically presents at birth as a hard, nontender mass in the hemiscrotum, usually with underlying dark discoloration of the skin and fixation of the skin to the mass. This picture is characteristic of infarction of the testis caused by previously occurring torsion. Postnatal torsion presents with more classic, acute inflammation, including erythema and tenderness. A report of a previously normal scrotum at delivery suggests an acute event. The difference is important because postnatal torsion requires

emergent exploration and treatment with detorsion and fixation.

Testicular salvage in perinatal torsion generally is rare, but some have reported surprisingly good salvage rates. If there is any question of the timing of the torsion, prompt exploration is the best course unless underlying medical conditions make general anesthesia unduly risky. Color Doppler ultrasonography may be useful in questionable cases. For patients experiencing prenatal torsion and presumed infarction of the testes, the classic teaching has been that surgical exploration is not indicated and salvage rates are negligible. This doctrine, however, has been challenged more recently, given reports of asynchronous torsion and the devastating consequences of loss of the remaining contralateral testis.

Torsion of the Contralateral Testis

Although torsion of the contralateral testis is extremely rare, many clinicians, fueled by fear of litigation, have become more aggressive with surgical exploration to fix the contralateral side and prevent future torsion. This is an area of considerable controversy. Unless medical conditions make anesthesia unduly risky, it has been our practice to explore these testes early to prevent contralateral torsion and ascertain the correct diagnosis because testicular teratoma or meconium/blood in a hernia sac may present with the same findings.

Many surgeons prefer an inguinal approach to the involved side, which allows easier delivery and removal of the necrotic, fixed gonad. The inguinal approach also is more appropriate when an alternate diagnosis is suspected. Contralateral exploration is accomplished through a transverse scrotal incision, with placement of the testis in a dartos pouch between the external spermatic fascia of the scrotum and the dartos layer. This technique is less traumatic to the small, delicate gonad and probably accomplishes better fixation than does suturing.

Mimics of Testicular Torsion

True bacterial epididymitis/orchitis is rare in children, but commonly is identified inaccurately as the cause of scrotal pain in the absence of testicular torsion. Inflammation of the testis and epididymis in the adult commonly results from bacterial epididymitis or epididymo-orchitis that extends from the bladder and urethra in retrograde fashion, especially in postpubertal, sexually active males.

Torsion of the appendix testis or appendix epididymis is a common cause of acute scrotal pain and frequently is misdiagnosed as acute epididymitis or epididymo-orchitis,

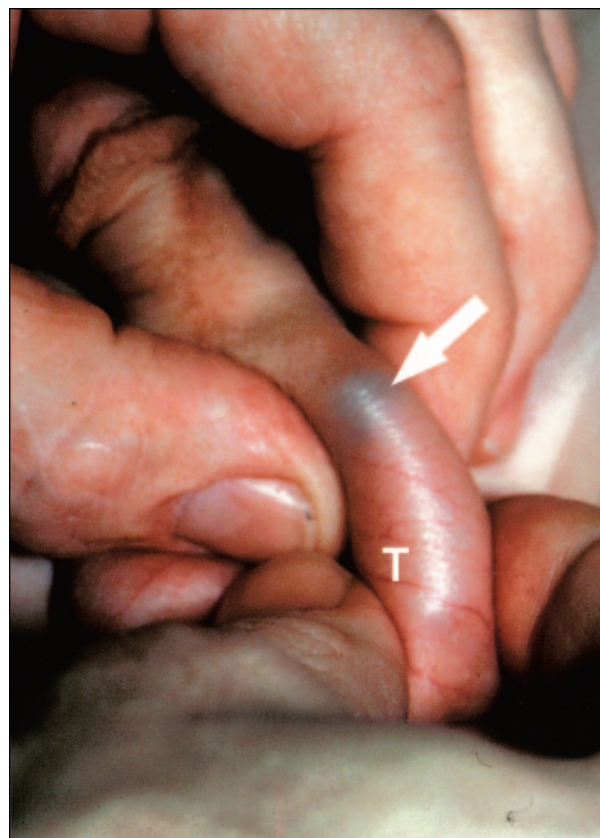

Figure 3. "Blue dot" sign of torted testicular appendage. Testicle (T) isolated in lower scrotum and torted appendage (white arrow) in upper scrotum.

implying a bacterial origin. The testicular appendage is a remnant of the Müllerian duct, whereas the epididymal appendages are of Wolffian duct origin. Torsion of an appendage occurs more commonly in the prepubertal age group. It is theorized that this event results from hormonal stimulation, which increases the mass of the pedunculated structures, making them susceptible to twisting.

The sudden onset of pain from torsion of an appendage can mimic testicular torsion. Findings on urinalysis are uniformly normal. Classically, torsion of the appendage is associated with the blue-dot sign, in which the infarcted appendage can be seen as a subtle blue mass through the scrotal skin (Fig. 3). Early in the condition, the appendage can be palpated and is exquisitely and focally tender to palpation. As local inflammation occurs, however, the epididymis, testis, and superficial tissues become edematous, and the diagnosis becomes more difficult to make. Early ultrasonography can be diagnostic, showing the discrete appendage; later, however, the

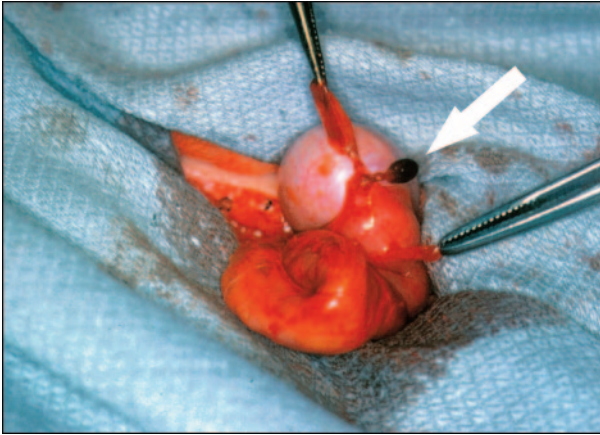


Figure 4. Intraoperative example of torsed appendage of testicle (white arrow) with two other nontorsed appendages held in forceps.

study may show only increased blood flow to the adjacent epididymis and testis and possibly a reactive hydrocele, resulting in the misdiagnosis of acute epididymitis or epididymoorchitis.

Torsion of the appendage is a self-limited condition that responds best to nonsteroidal anti-inflammatory medications and comfort measures such as limited activity and a warm compress. As the appendage infarcts and necroses, the pain resolves. Such torsion can recur because five appendages potentially may experience torsion (appendix testis, appendix epididymis, paradidymis-organ of Giraldes, superior and inferior vas aberrans of Haller). Surgical intervention is indicated when the diagnosis of testicular torsion cannot be eliminated or when the symptoms are prolonged and do not resolve spontaneously. The torsed appendage can be excised easily through a small scrotal incision, resulting in relief of symptoms (Fig. 4).

Classic bacterial epididymitis generally has a slow onset and is characterized by scrotal pain and swelling that worsens over days rather than hours. Usually, there is no nausea or vomiting. Bacteria are believed to reach the epididymis in retrograde fashion via the ejaculatory ducts and can be associated with a urinary tract infection or urethritis. A positive result from urinalysis and culture, or urethral swab in sexually active adolescents, suggests the diagnosis. *Chlamydia* and gonococci are described as the classic causative agents in the sexually active individual; common urinary pathogens, however, including coliforms and *Mycoplasma* sp, are more probable in younger children. When studies suggest a bacterial infection, antibiotics are indicated. Just as for any urinary tract infection in a boy, radiographic imaging, including renal and

bladder ultrasonography and voiding cystourethrography, should be obtained after the infection has resolved. Anatomic abnormalities such as ectopic ureter to the vas, ejaculatory duct, or seminal vesical; ejaculatory duct obstruction; or urethral valves are uncommon but should be excluded.

Viral infections likely are an underappreciated cause for acute epididymitis and usually are diagnosed presumptively. Mumps orchitis occurs in about one third of postpubertal boys affected by the virus and, fortunately, is rare in the modern era of immunization. Adenovirus, enterovirus, influenza, and parainfluenza virus infections also have been described. Management is supportive, antibiotics are not indicated, and the pain syndrome generally is self-limited. Aggressive testing usually is not warranted, but viral cultures and serologic studies may be useful in clustered familial or community cases.

Voiding dysfunction is a common but underreported cause of scrotal pain that frequently is unrecognized unless the diagnosis is sought. Recurrent bouts of scrotal pain warrant this consideration, especially if the pain is bilateral. The pathophysiology involves bladder instability causing high pressure in a patient who is voiding against a voluntarily closed external sphincter. It is common to see dilation of the posterior urethra (“spinning-top” urethra) on voiding in affected children during voiding cystourethrography. Urine may be forced up the ejaculatory duct, resulting in local inflammation, and a “chemical” epididymitis or epididymoorchitis may result. Renal and bladder ultrasonography may show a thickened bladder wall and is useful in ruling out ureteral ectopia to the ejaculatory duct or vas deferens as a potential cause in recurrent cases. There is no pathognomonic test for voiding dysfunction, but the history often reveals urinary urgency, incontinence, a staccato (stop-start) urinary stream indicative of inappropriate sphincter activity, and occult constipation. Treatment of affected children via a timed voiding regimen, dietary modification, aggressive management of constipation, and sometimes anticholinergic or alpha-antagonist medication is effective.

Henoch-Schönlein purpura is a vasculitic syndrome that can affect the skin, joints, gastrointestinal tract, and genitourinary system. Pain, erythema, and swelling of the scrotum and spermatic cord occur in up to one third of patients. The swelling seems to occur more commonly in boys younger than 7 years of age. Scrotal findings and onset of pain may mimic testicular torsion, but Doppler ultrasonography reveals good blood flow to the testes. The history may document other systemic symptoms such as purpura of the skin, joint pain, and hematuria.

Usually supportive measures are adequate, but systemic steroids sometimes are helpful. Despite the rarity of overlapping diagnoses, Henoch-Schönlein purpura and torsion of the testis have been reported together.

Scrotal swelling of unknown cause is termed idiopathic scrotal edema or sometimes “summer penile syndrome.” The syndrome is characterized by thickening and erythema of the scrotum, but the testes generally are not involved. Pruritus may be present, but the condition is not usually painful. Ultrasonography shows normal testicular blood flow and usually is not required. Other causes should be sought to rule out cellulitis from an adjacent infection (inguinal, perirectal, or urethral). Undoubtedly, many cases of contact dermatitis, insect bites, and minor trauma are given this diagnosis. Management is supportive, and antihistamines or topical steroids may relieve symptoms considerably. Oral antibiotics are administered if cellulitis is a concern.

Other causes of the acutely painful scrotum that must be considered include hernia, hydrocele, sexual abuse or other trauma, and neoplasia. Usually, the history, physical examination, and selective imaging can differentiate these causes of scrotal swelling from testicular torsion.

Conclusion

Acute scrotal pain in the child or adolescent male always should be treated as an emergent condition. Prompt diagnosis and surgical treatment of torsion of the spermatic cord is imperative to avoid permanent ischemic damage to the testicle. Fortunately, most of the conditions causing this syndrome are nonurgent. An accurate diagnosis can be made with the history, physical examination, and imaging.

Summary

- Based on strong research evidence, prompt operative intervention for torsion of the testicle is imperative for testicular survival (Bartsch 1980).
- Based on strong research evidence, scrotal color

Doppler ultrasonography is a helpful adjunct in differentiating testicular torsion from other nonemergent conditions of acute scrotal swelling (Baker 2000).

- Based on strong research evidence, testicular torsion is diagnosed on the basis of history, physical examination, and imaging studies. When testicular torsion cannot be excluded, exploration is warranted (Kalfa 2004).

Suggested Reading

- Baker LA, Sigman D, Mathews RI, Benson J, Docimo SG. An analysis of clinical outcomes using color Doppler testicular ultrasound for testicular torsion. *Pediatrics*. 2000;105:604–607
- Bartsch G, Frank S, Marberger H, Mikuz G. Testicular torsion: late results with special regard to fertility and endocrine function. *J Urol*. 1980;124:375–378
- Bukowski TP, Lewis AG, Reeves D, Wacksman J, Sheldon CA. Epididymitis in older boys: dysfunctional voiding as an etiology. *J Urol*. 1995;154:762–765
- Gatti JM, Murphy JP. Current management of the acute scrotum. *Semin Pediatr Surg*. 2007;16:58–63
- Haecker FM, Hauri-Hohl A, von Schweinitz D. Acute epididymitis in children: a 4-year retrospective study. *Eur J Pediatr Surg*. 2005;15:180–186
- Hutson J. Undescended testis, torsion, and varicocele. In: Grosfeld JL, O’Neill JA, Coran AG, Fonkalsrud EW, eds. *Pediatric Surgery*. Philadelphia, Pa: Mosby Elsevier; 2006:1193–1214
- Kalfa N, Veyrac C, Baud C, Couture A, Averous M, Galifer RB. Ultrasonography of the spermatic cord in children with testicular torsion: impact on the surgical strategy. *J Urol*. 2004;172:1692–1695
- Karmazyn B, Steinberg R, Livne P, et al. Duplex sonographic findings in children with torsion of the testicular appendages: overlap with epididymitis and epididymoorchitis. *J Pediatr Surg*. 2006;41:500–504
- Nagler HM, White RD. The effect of testicular torsion on the contralateral testis. *J Urol*. 1982;128:1343–1348
- Sessions AE, Rabinowitz R, Hulbert WC, Goldstein MM, Mevorach RA. Testicular torsion: direction, degree, duration and disinformation. *J Urol*. 2003;169:663–665
- Somekh E, Gorenstein A, Serour F. Acute epididymitis in boys: evidence of a post-infectious etiology. *J Urol*. 2004;171:391–394
- Sorensen MD, Galansky SH, Striegl AM, Mevorach R, Koyle MA. Perinatal extravaginal torsion of the testis in the first month of life is a salvageable event. *Urology*. 2003;62:132–134

PIR Quiz

Quiz also available online at www.pedsinreview.org.

9. During a health supervision visit, a 13-year-old boy who is new to your practice relates that over the past 2 years he has had three bouts of severe unilateral scrotal pain that have resolved over several minutes. Your examination reveals genitalia and pubic hair at Sexual Maturity Rating (SMR) 4. No clear abnormalities are identified on palpation. Your chief concern should be the possibility of:
 - A. Intermittent testicular torsion.
 - B. Intermittent torsion of the appendix testis.
 - C. Recurrent epididymitis.
 - D. Recurrent orchitis.
 - E. Recurrent thrombosis of a varicocele.
10. Physical examination of the affected hemiscrotum early in the course of acute testicular torsion is *most* likely to reveal:
 - A. A low-riding testicle.
 - B. A small blue mass in the superior testis.
 - C. Anterior location of the epididymis.
 - D. Focal tenderness in the superior portion of the testis.
 - E. Purpura of the scrotal skin.
11. Ten hours ago, a previously healthy 14-year-old boy developed sudden excruciating pain in his right hemiscrotum. He recalls no injury or antecedent illness. He is sexually active. On physical examination, the right hemiscrotum is red, swollen, and exquisitely tender. The *most* appropriate first step is to:
 - A. Attempt manual detorsion.
 - B. Order color Doppler ultrasonography.
 - C. Order urinalysis.
 - D. Order radionuclide imaging.
 - E. Proceed immediately to the operating room.
12. A previously healthy 8-year-old boy presents to the emergency department 1 hour after developing the acute onset of right-sided scrotal pain. Aside from obvious discomfort, findings of his general examination are normal. Genitalia are at SMR 1. Examination of the contents of the right hemiscrotum is made difficult by edema and tenderness. Urinalysis results are normal. Color Doppler ultrasonography reveals increased blood flow to the right epididymis and testis. These data *best* support a diagnosis of:
 - A. Acute epididymitis.
 - B. Acute testicular torsion.
 - C. Henoch-Schönlein purpura.
 - D. Summer penile syndrome.
 - E. Torsion of the appendix testis.
13. A previously healthy 14-year-old boy has been experiencing left scrotal pain for the past 3 days. He recalls no injury or antecedent illness. He is sexually active. His general examination findings are normal, but his left hemiscrotum is warm, swollen, and slightly tender to palpation. Both testes are palpable at the same level. A urinalysis reveals 40 white blood cells per high-power field with a negative nitrite test. The *most* appropriate next step is to:
 - A. Apply cold compresses.
 - B. Attempt manual detorsion.
 - C. Begin oral antibiotics.
 - D. Order color Doppler ultrasonography.
 - E. Proceed immediately to the operating room.

Acute Testicular Disorders
John M. Gatti and J. Patrick Murphy
Pediatrics in Review 2008;29;235
DOI: 10.1542/pir.29-7-235

Updated Information & Services

including high resolution figures, can be found at:
<http://pedsinreview.aappublications.org/content/29/7/235>

References

This article cites 11 articles, 1 of which you can access for free at:
<http://pedsinreview.aappublications.org/content/29/7/235#BIBL>

Subspecialty Collections

This article, along with others on similar topics, appears in the following collection(s):
Genital System Disorders
http://pedsinreview.aappublications.org/cgi/collection/genital_system_disorders
Renal Disorders
http://pedsinreview.aappublications.org/cgi/collection/renal_disorders

Permissions & Licensing

Information about reproducing this article in parts (figures, tables) or in its entirety can be found online at:
</site/misc/Permissions.xhtml>

Reprints

Information about ordering reprints can be found online:
</site/misc/reprints.xhtml>

American Academy of Pediatrics

DEDICATED TO THE HEALTH OF ALL CHILDREN™

